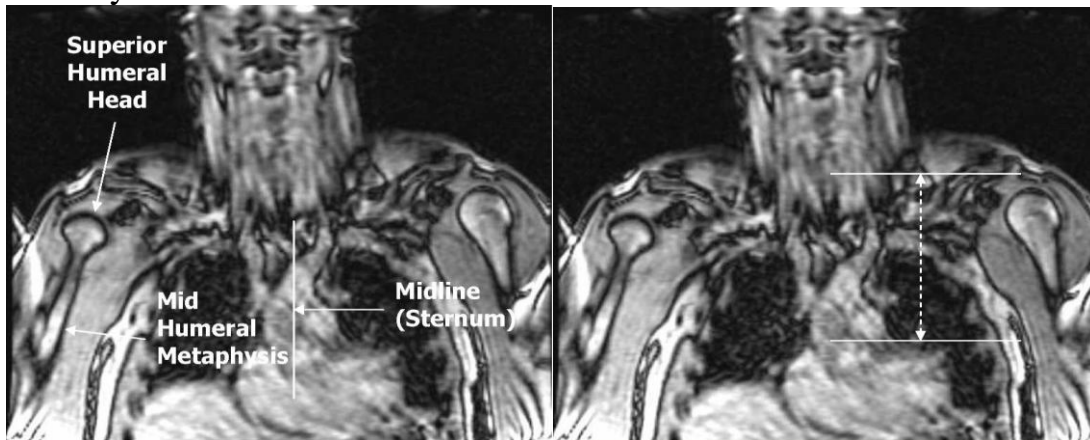


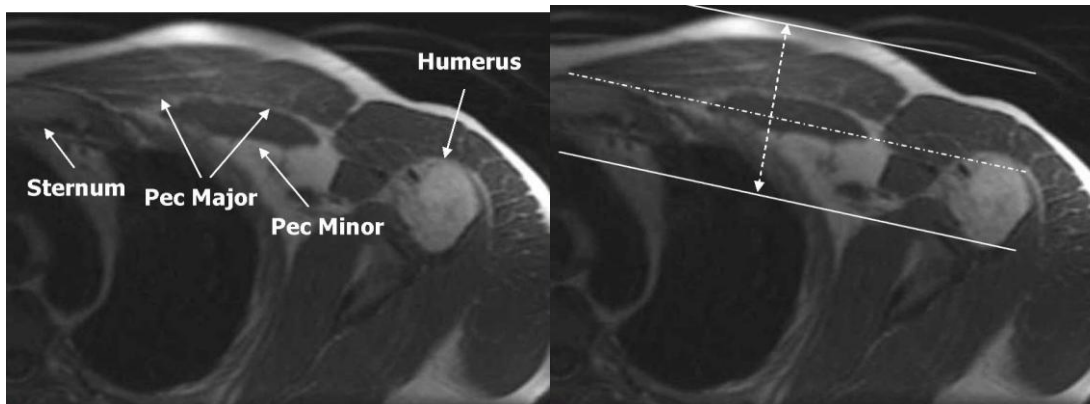
MRI Pectoralis Muscle without contrast

<http://mriprotocol.blogspot.com/2011/11/pectoralis-muscle-mri-anatomy.html>

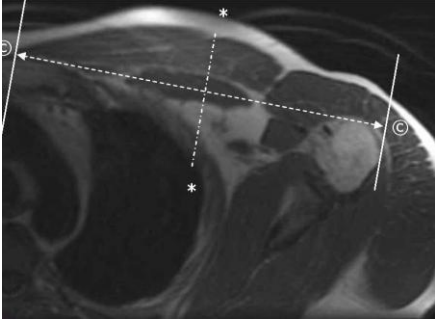
Axial Plane: Scan from superior humeral head through the xyphoid process. The field of view should include the sternum medially, and the humeral shaft laterally:



Coronal Plane: Prescribe a plane parallel to the line from sternum through anterior humerus. Scan from skin through posterior humeral head. Field of view should include the sternum and humerus:



Sagittal Plane: Prescribe plane perpendicular to coronal plane. Scan From sternum through lateral aspect of humerus:



- 1. Scout**
- 2. Bilateral Axial PD FatSat**
- 3. Axial T1**
- 4. Axial T2 FatSat**
- 5. Coronal T1**
- 6. Coronal T2 FatSat/STIR**
- 7. Sag T2**